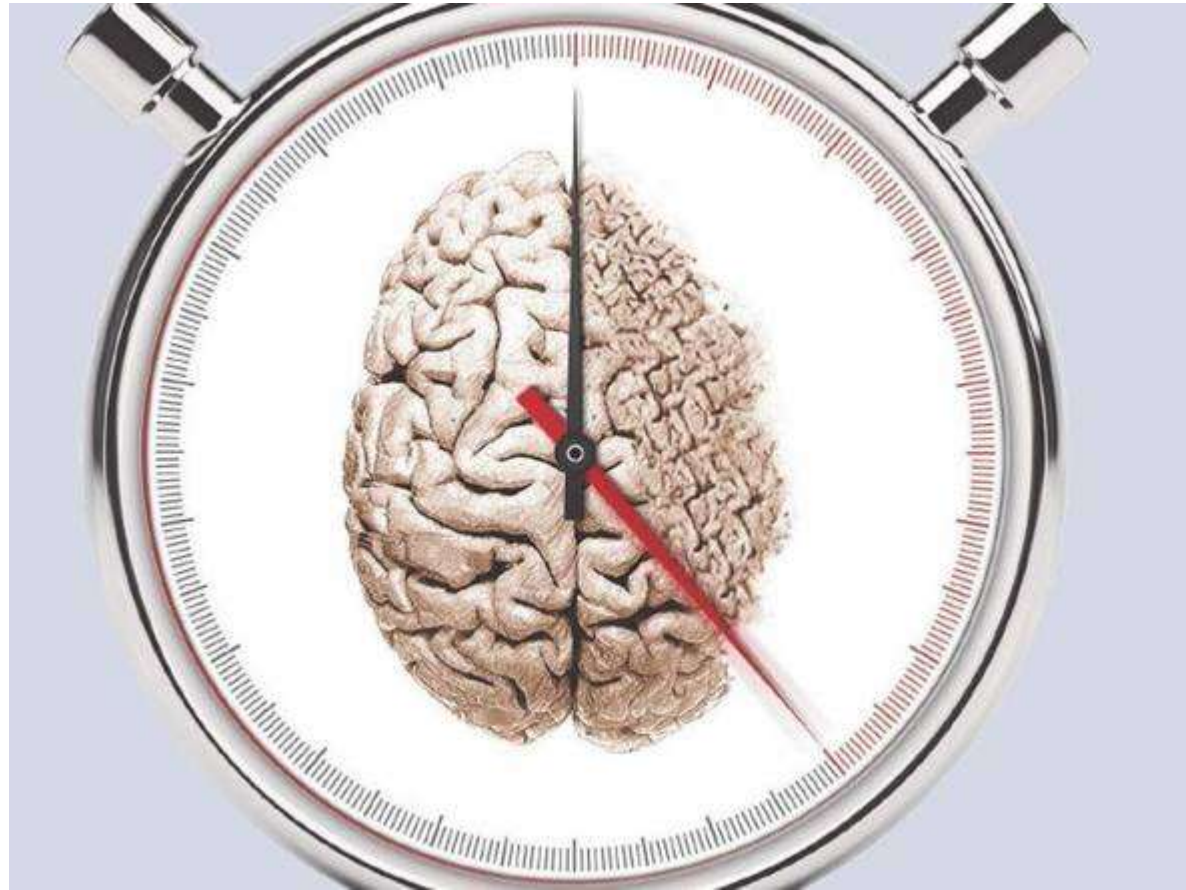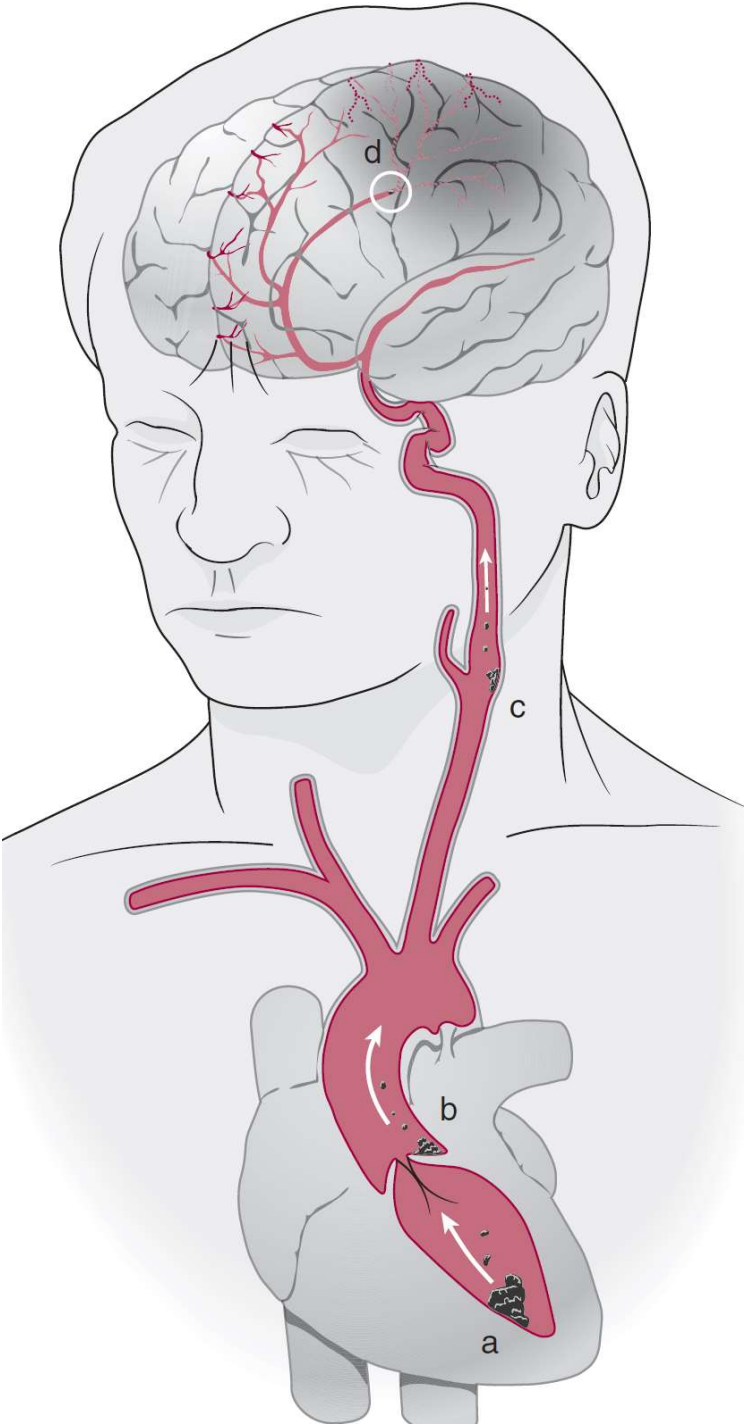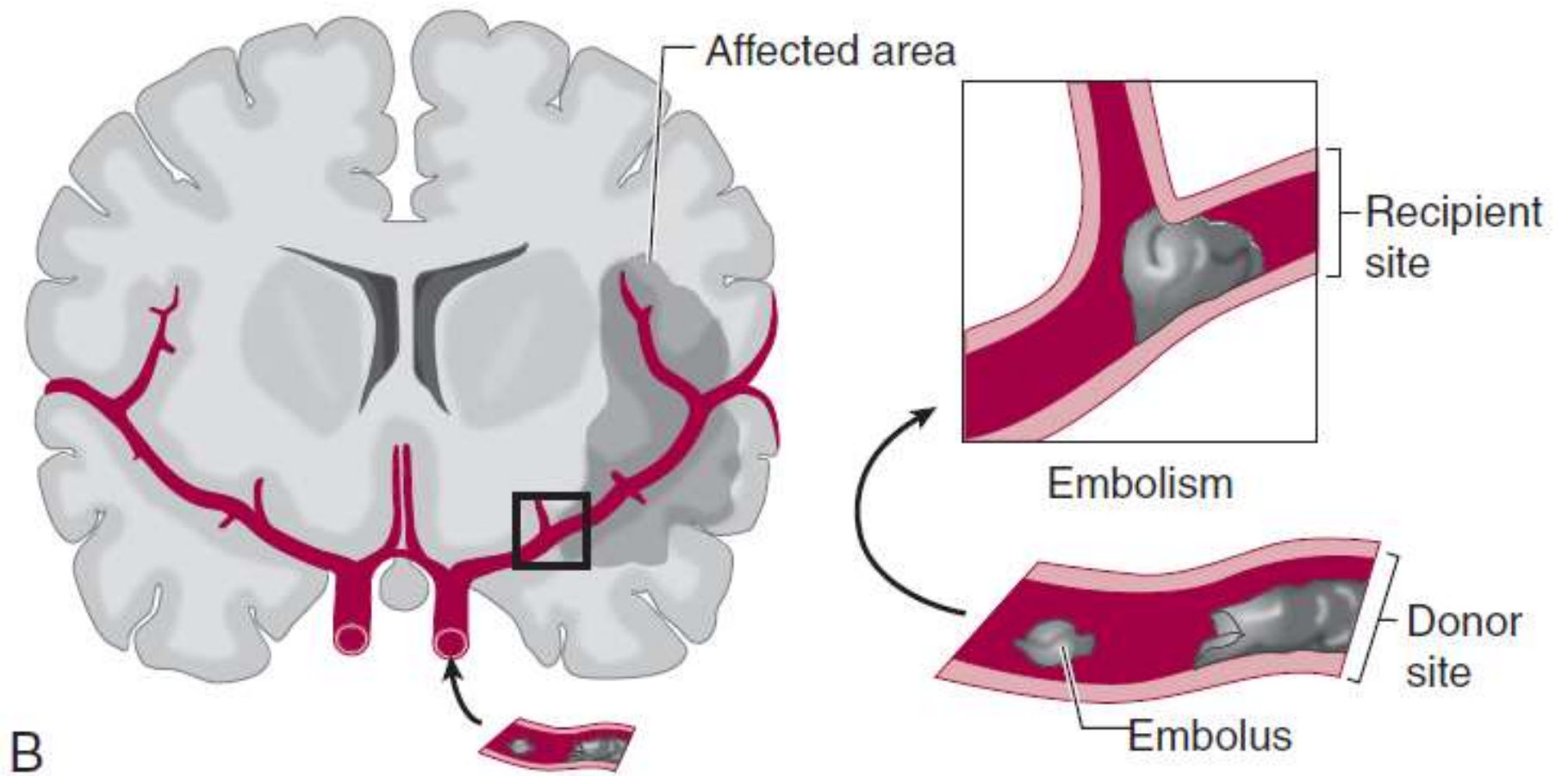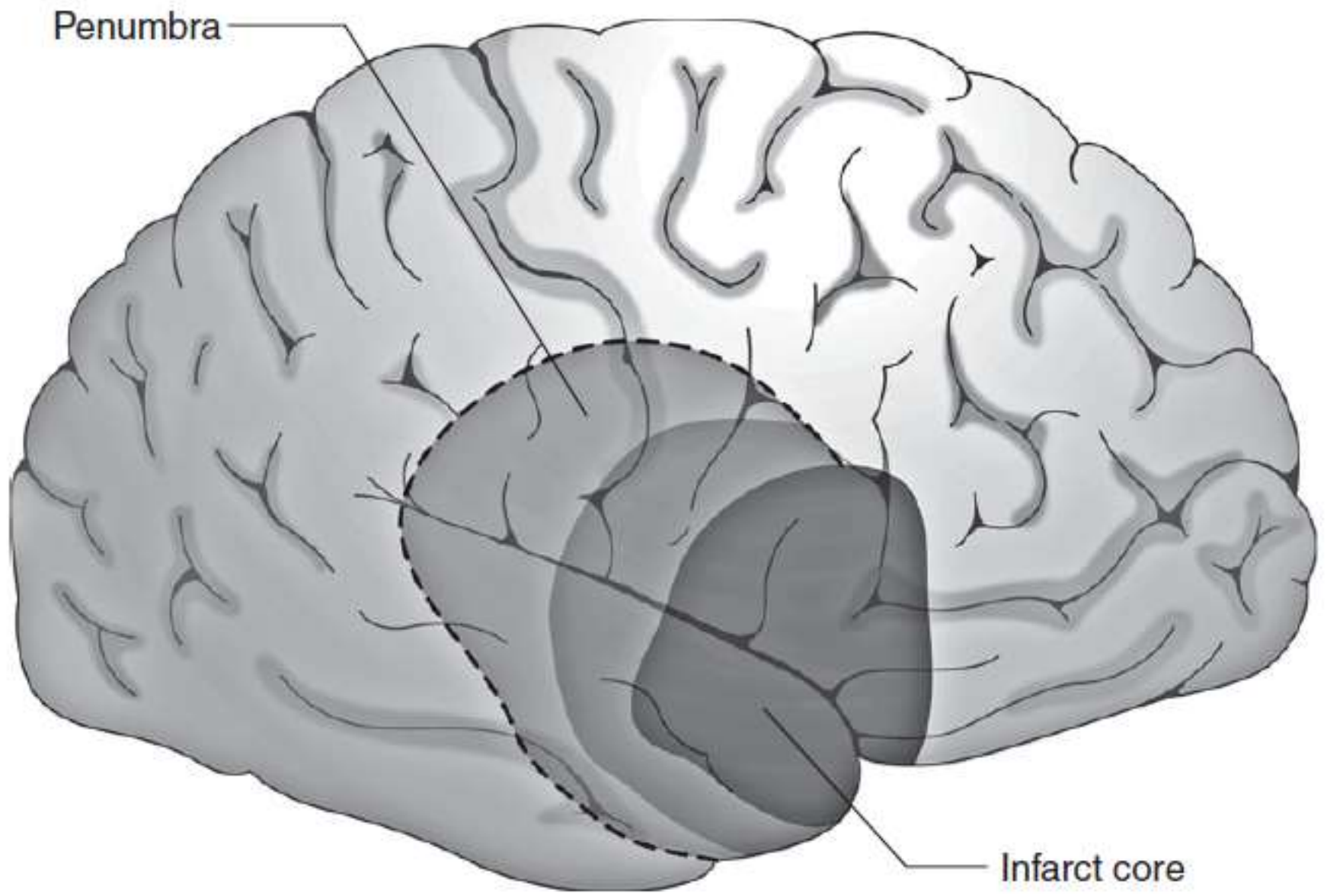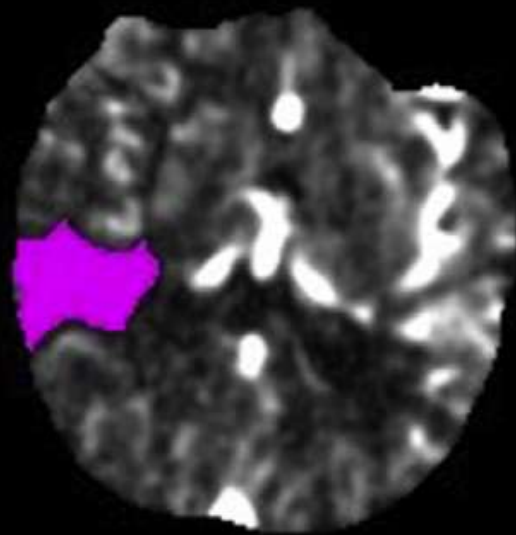


Penumbra

Infarct core

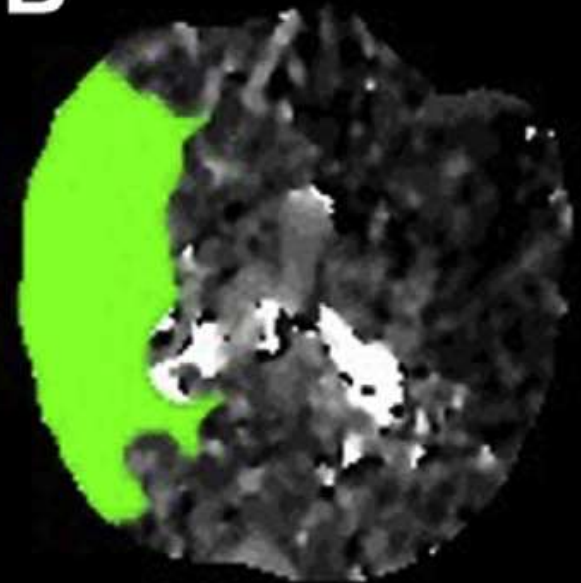
**Pre-  
Reperfusion**

**A**

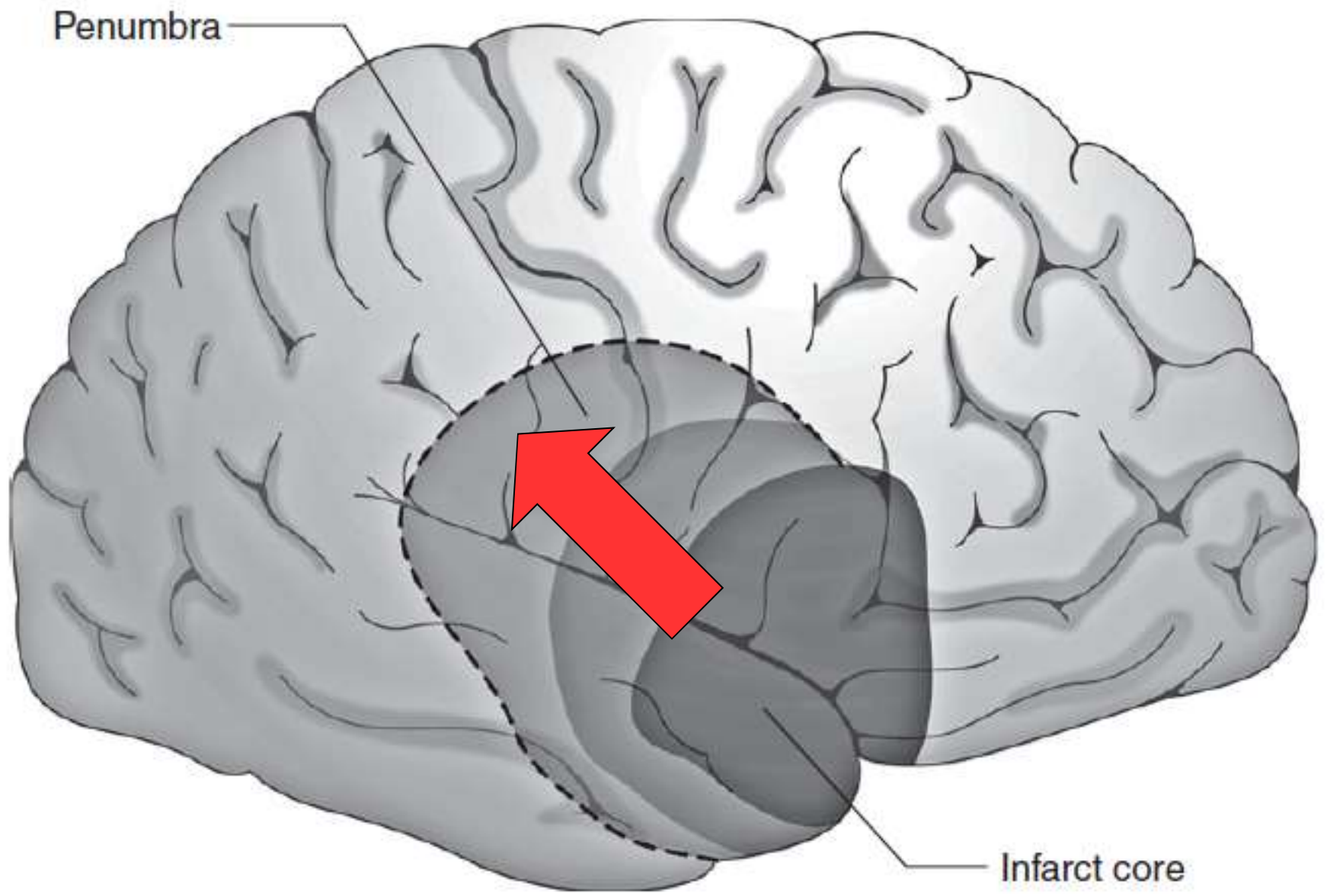


**rCBF < 30%**

**B**



**Tmax > 6.0s**



Penumbra

Infarct core

The NEW ENGLAND JOURNAL of MEDICINE

EDITORIALS



**Thrombolytic Therapy for Acute Stroke — Not a Moment to Lose**

Patrick Lyden, M.D.

# The New England Journal of Medicine

©Copyright, 1995, by the Massachusetts Medical Society

---

Volume 333

DECEMBER 14, 1995

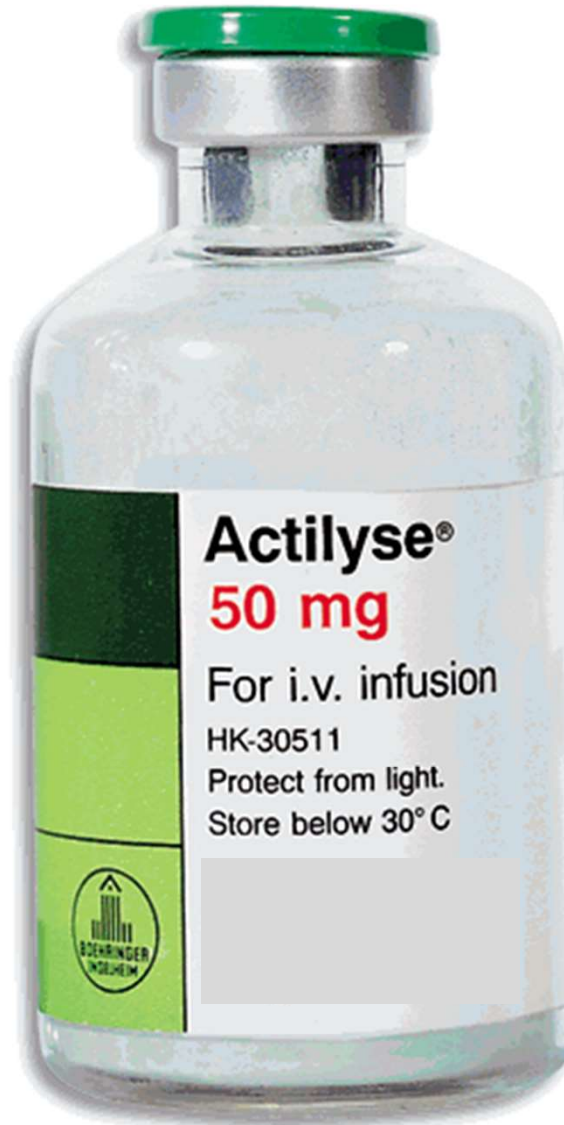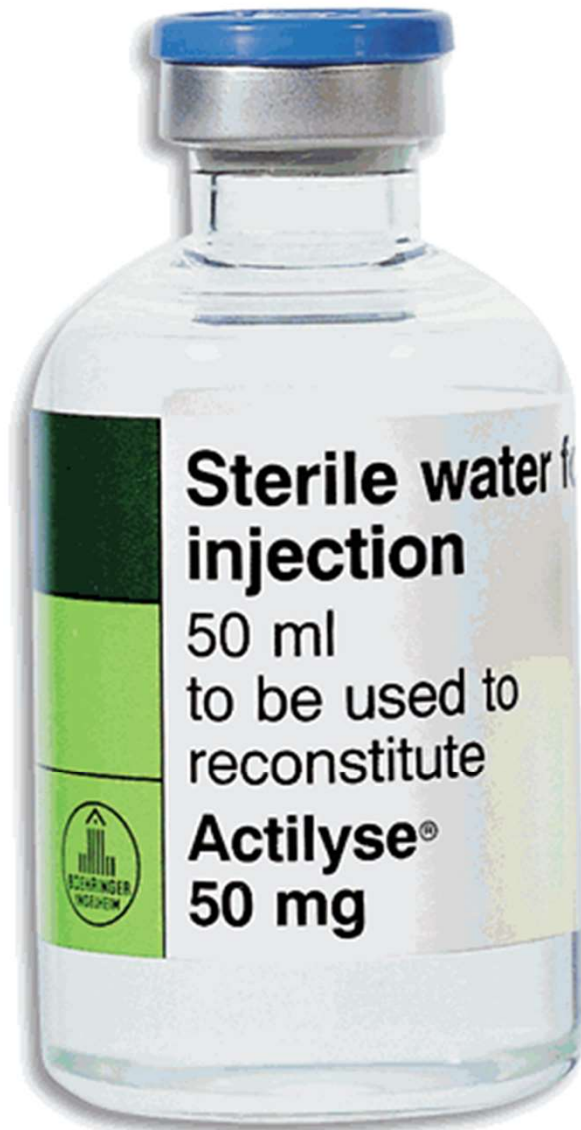Number 24

---

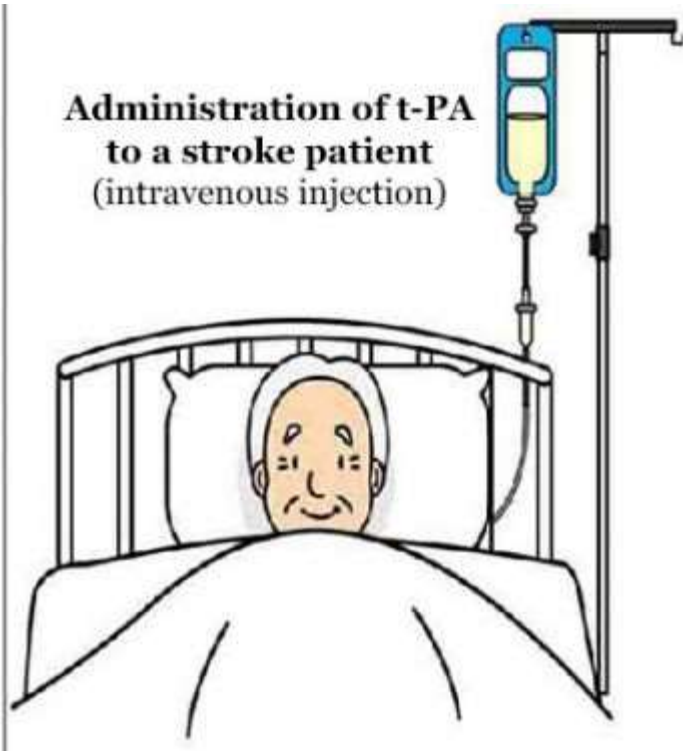
## **TISSUE PLASMINOGEN ACTIVATOR FOR ACUTE ISCHEMIC STROKE**

THE NATIONAL INSTITUTE OF NEUROLOGICAL DISORDERS AND STROKE rt-PA STROKE STUDY GROUP\*

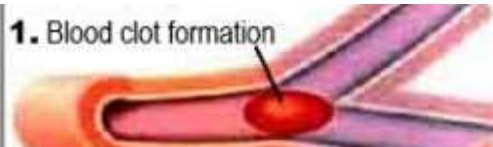
# TROMBOLISI SISTEMICA (E. V.)



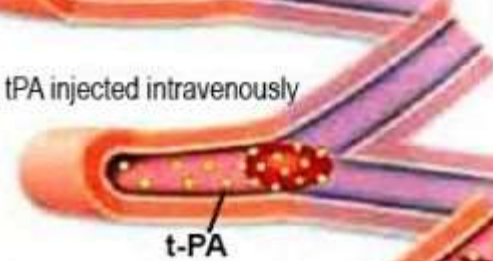
**Administration of t-PA  
to a stroke patient  
(intravenous injection)**



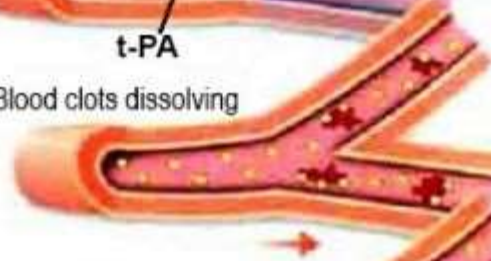**1. Blood clot formation**



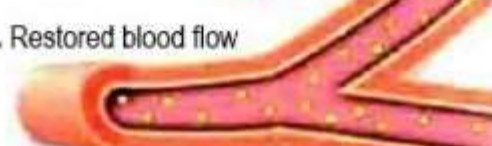
**2. tPA injected intravenously**

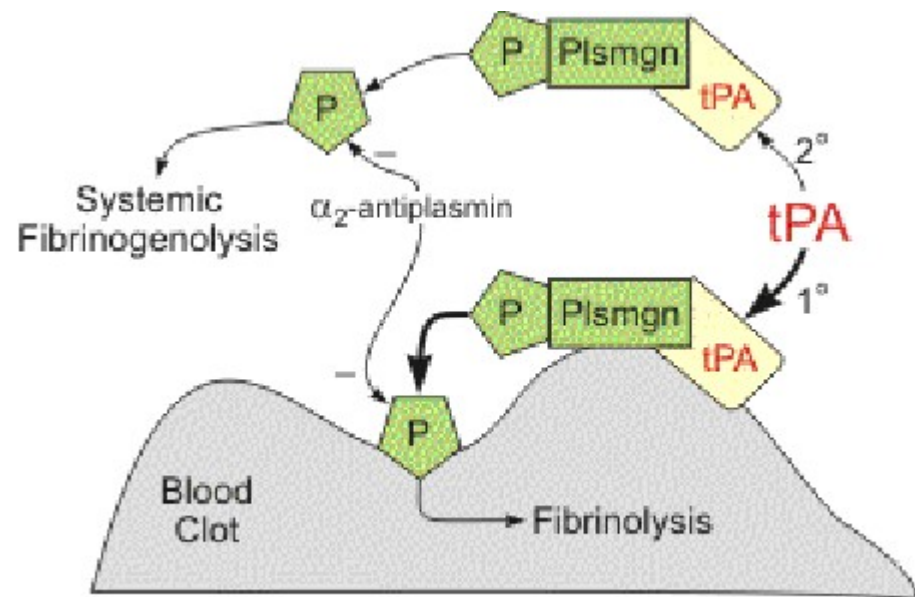


**3. Blood clots dissolving**



**4. Restored blood flow**





*The* NEW ENGLAND  
JOURNAL *of* MEDICINE

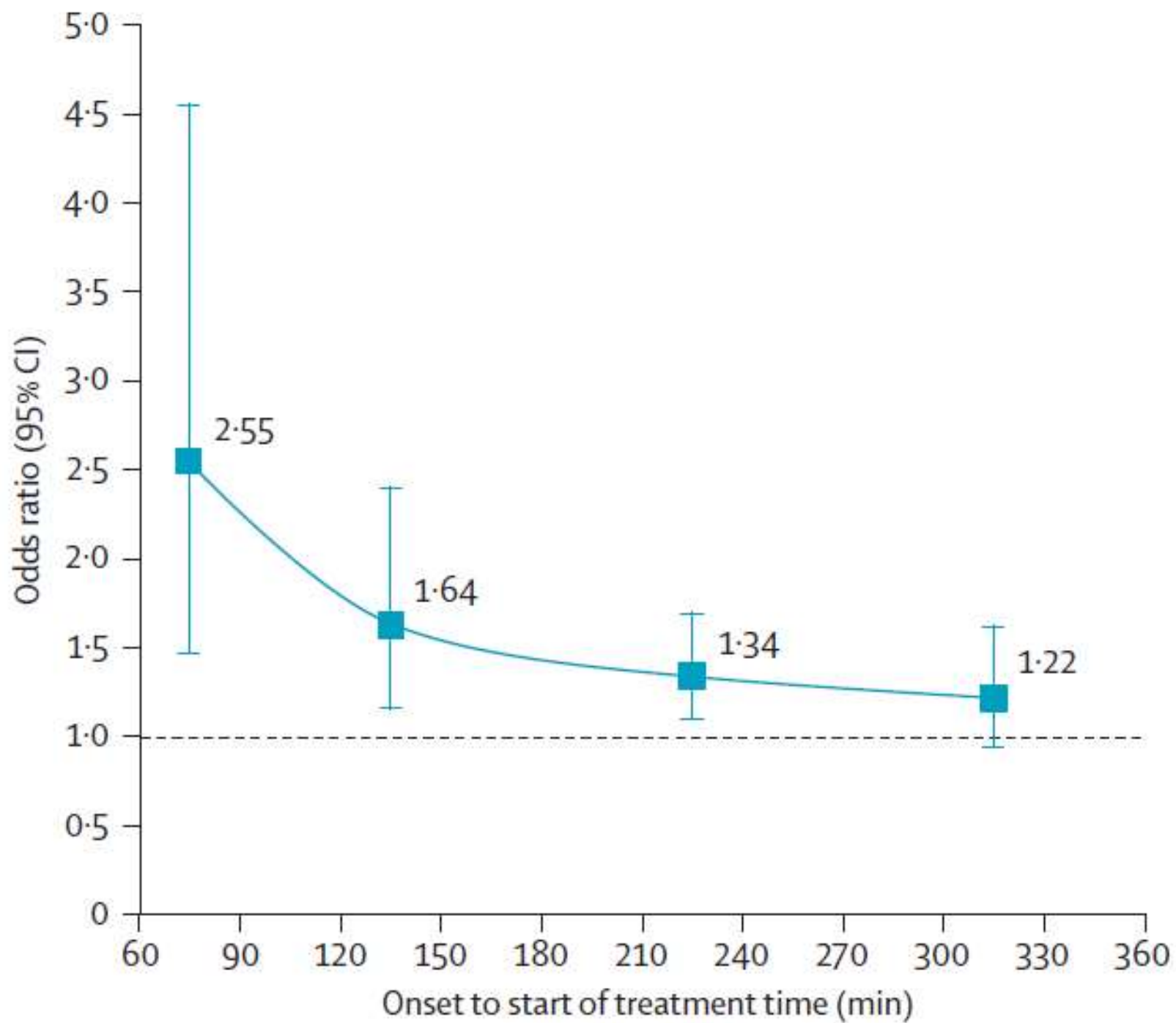
ESTABLISHED IN 1812

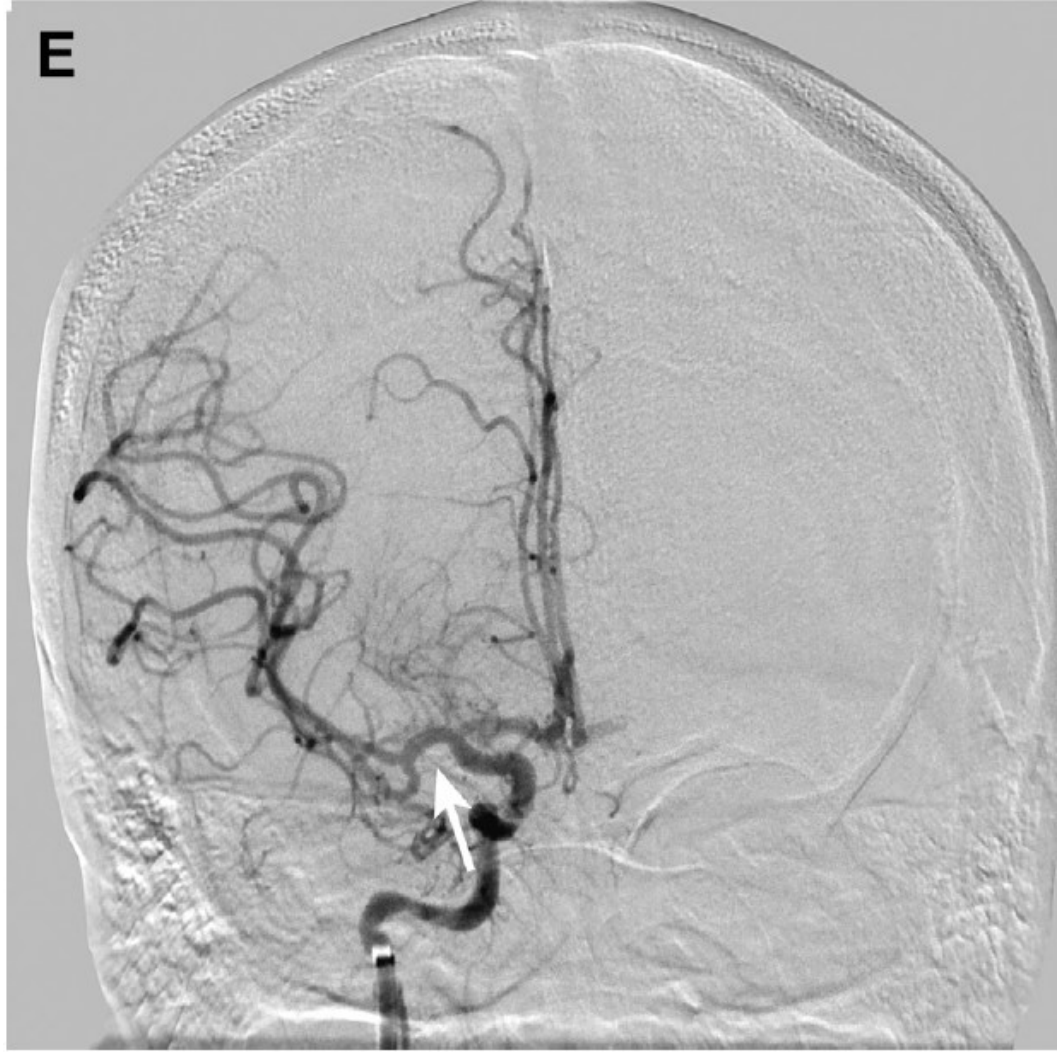SEPTEMBER 25, 2008

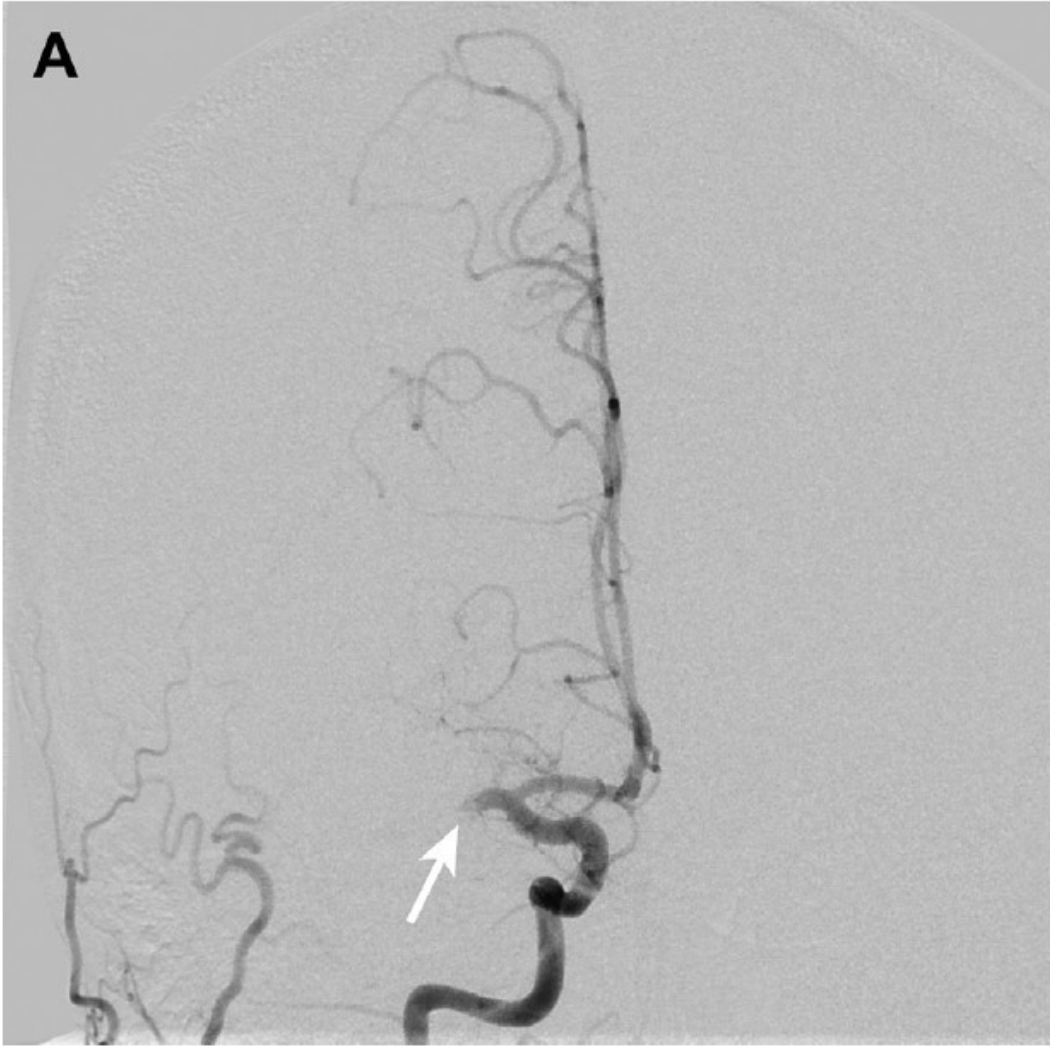
VOL. 359 NO. 13

Thrombolysis with Alteplase 3 to 4.5 Hours  
after Acute Ischemic Stroke

Werner Hacke, M.D., Markku Kaste, M.D., Erich Bluhmki, Ph.D., Miroslav Brozman, M.D., Antoni Dávalos, M.D.,  
Donata Guidetti, M.D., Vincent Larrue, M.D., Kennedy R. Lees, M.D., Zakaria Medeghri, M.D.,  
Thomas Machnig, M.D., Dietmar Schneider, M.D., Rüdiger von Kummer, M.D., Nils Wahlgren, M.D.,  
and Danilo Toni, M.D., for the ECASS Investigators\*



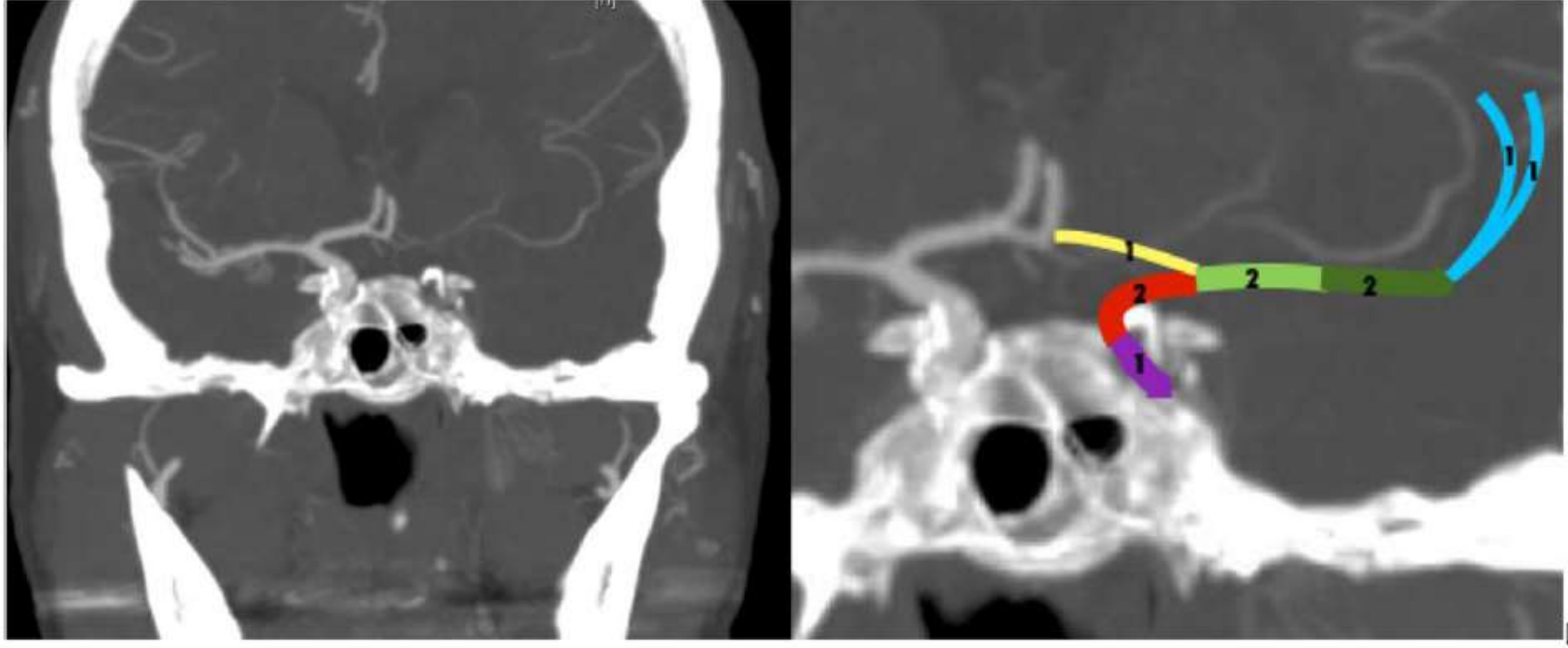


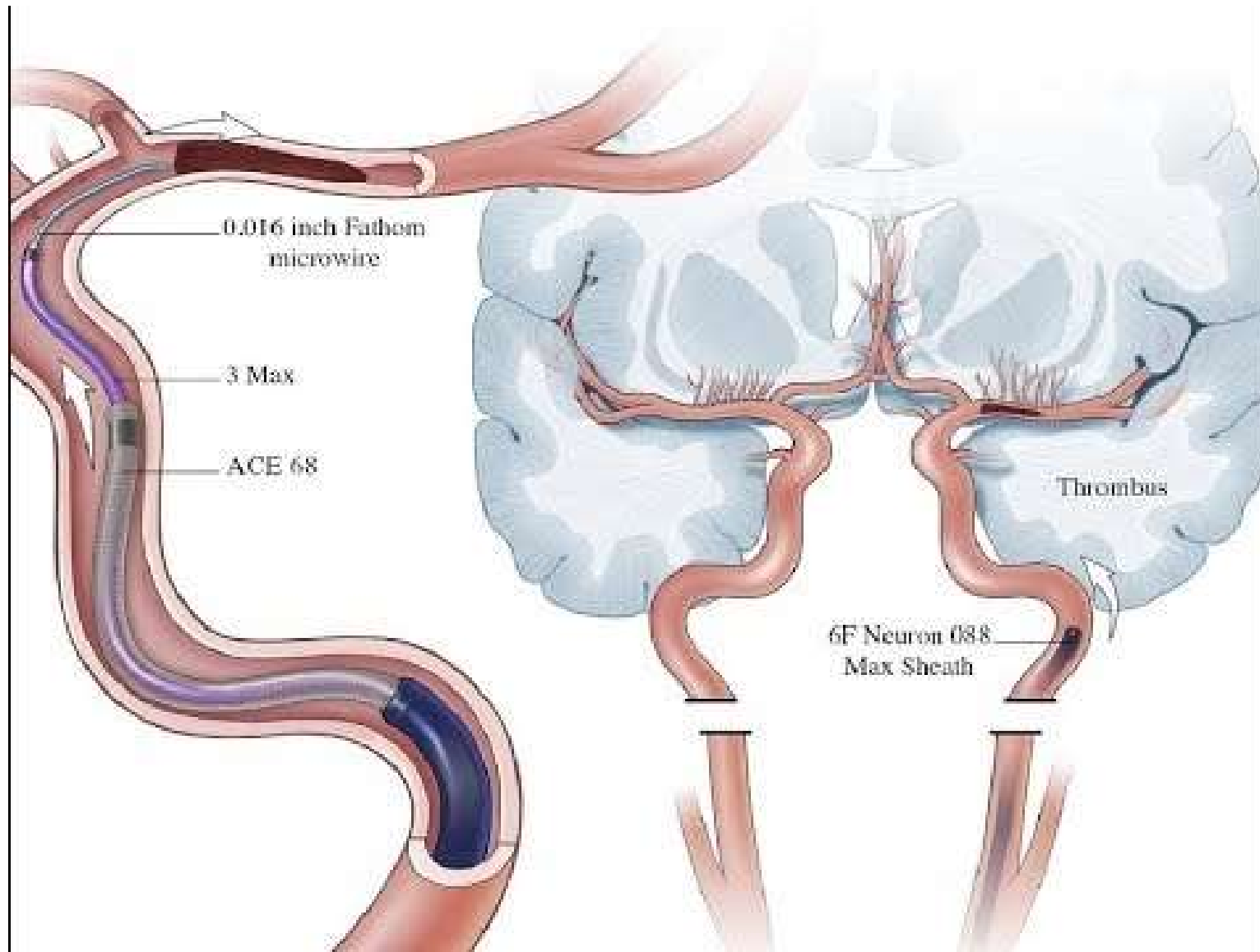


# Ricanalizzazione 1 ore dopo rTPA

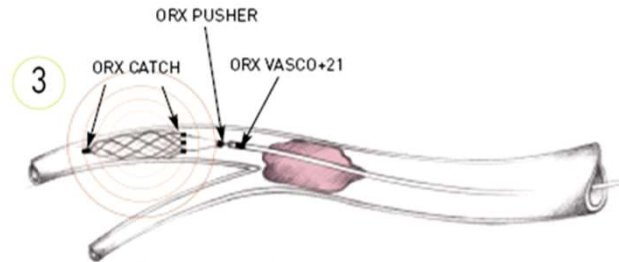
ICA (n=23)	M1 (n=34)	M2 (n=26)	M3 (n=44)
8.7%	35.3%	53.8%	65.9%

E

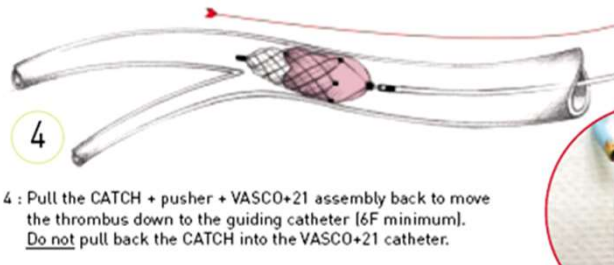




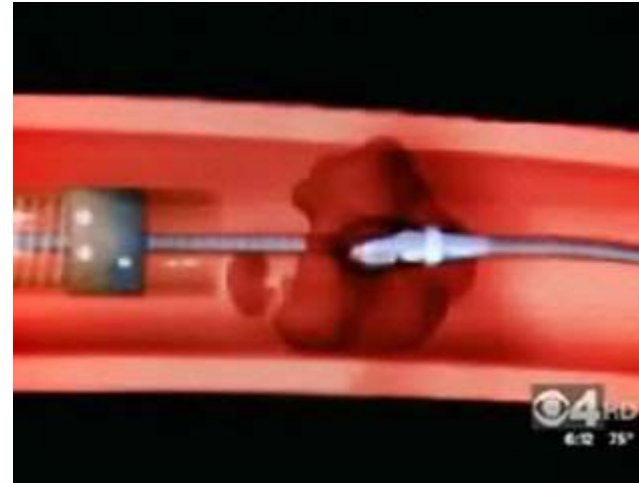
## Catch



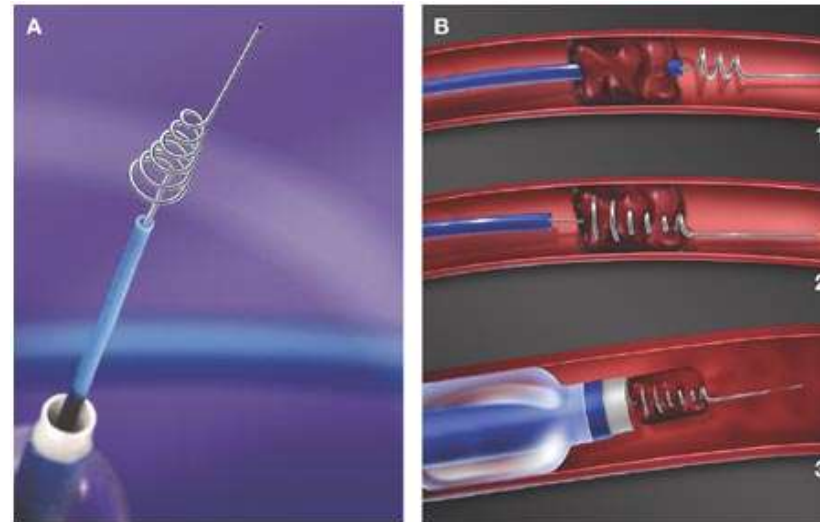
3 : Deploy the CATCH out of the VASCO+21 downstream from the thrombus by pulling the catheter.  
The radio-opaque marker of the VASCO+ should have over passed that of the  
The maximum diameter of the CATCH is 4 mm.



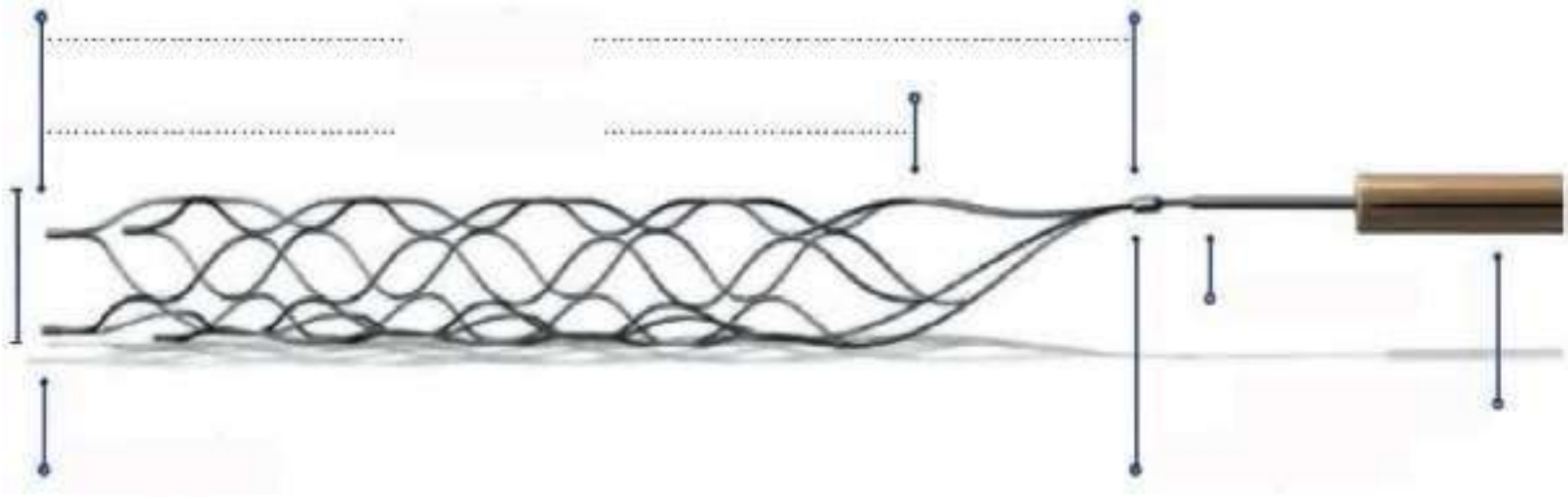
4 : Pull the CATCH + pusher + VASCO+21 assembly back to move the thrombus down to the guiding catheter [6F minimum].  
Do not pull back the CATCH into the VASCO+21 catheter.

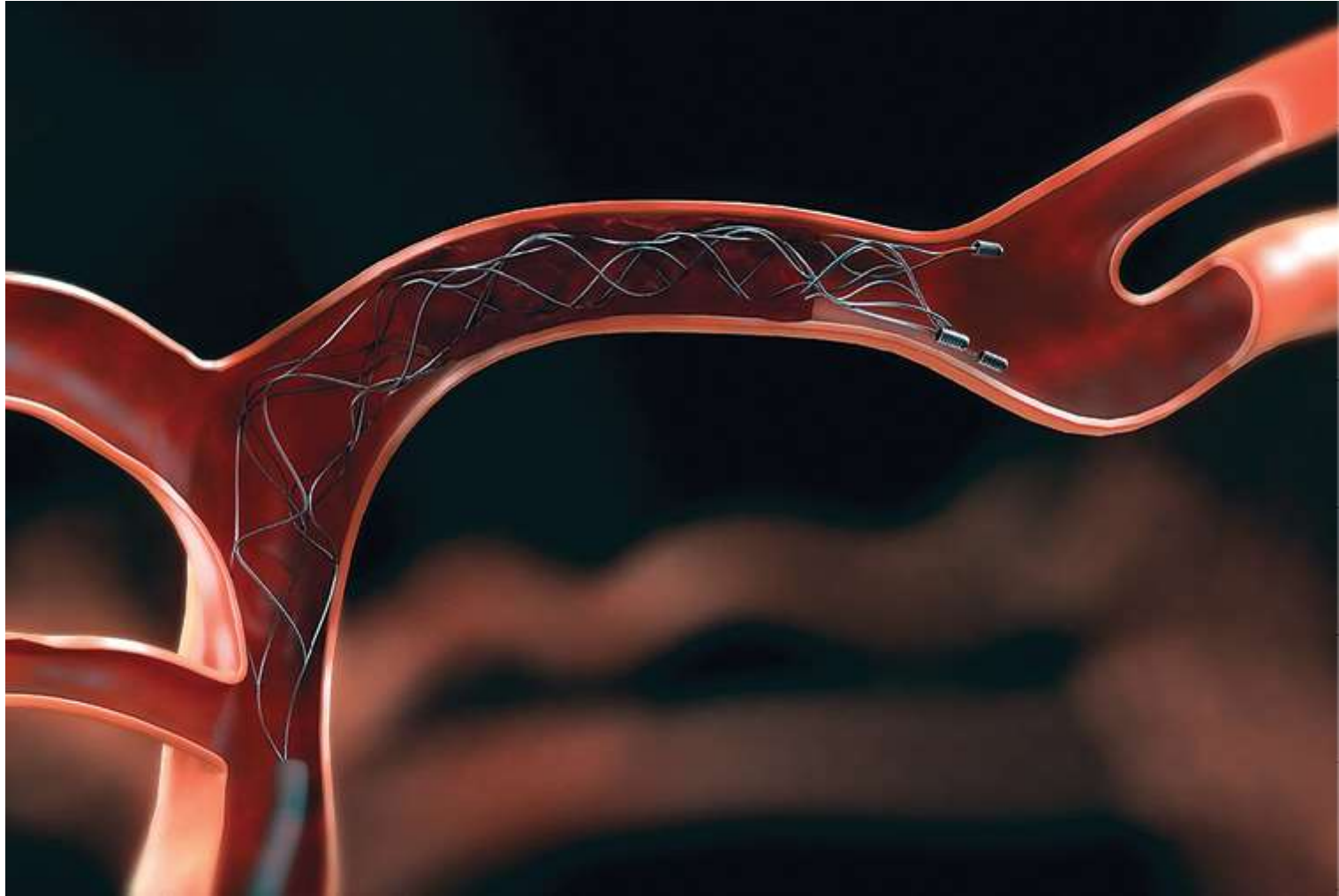


Penumbra



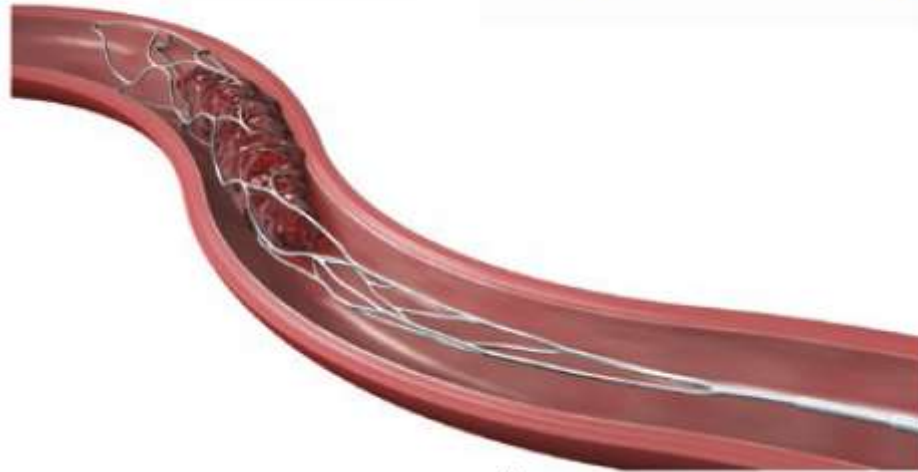
Merci






Copyright © 2014 Stryker  
NV00007165.AA

Bench Model Photo Trevo<sup>®</sup> XP ProVue Retriever  
Visible Under Fluoroscopy  
Image courtesy of Stryker Neurovascular



Trevo<sup>®</sup> XP ProVue Retriever secures clot during retrieval  
Image courtesy of Stryker Neurovascular



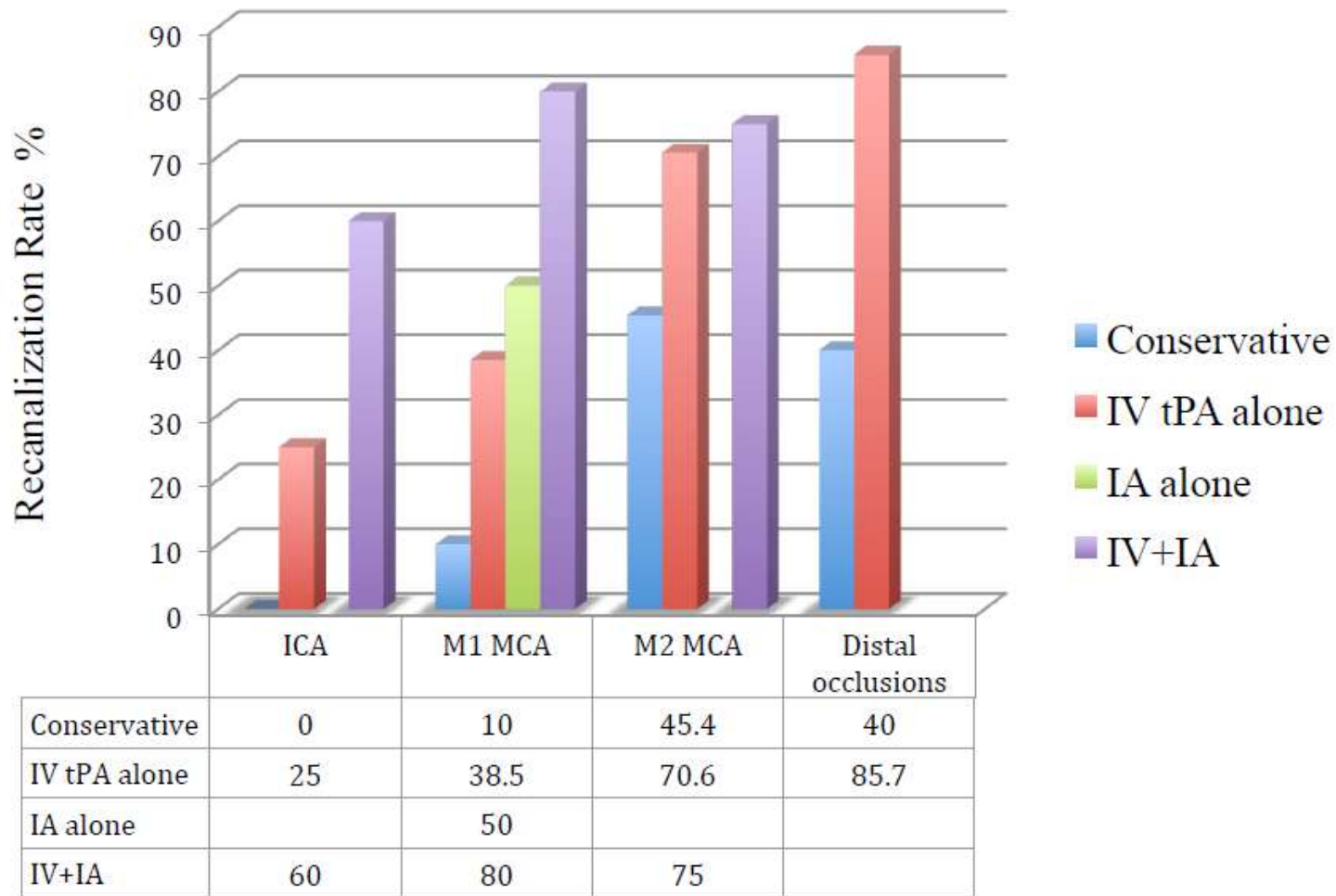
# Terapia Standard

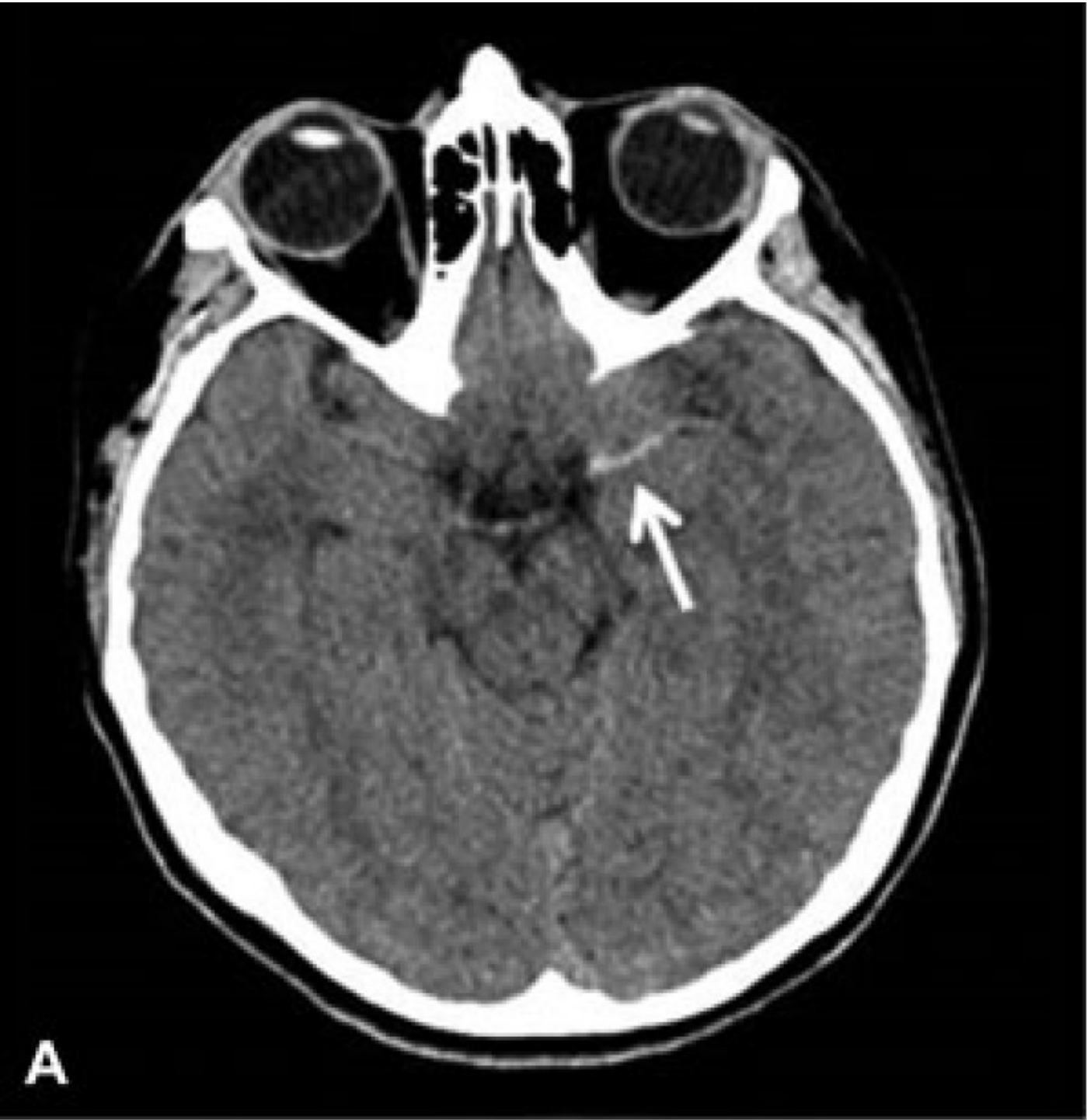## Vasi piccoli

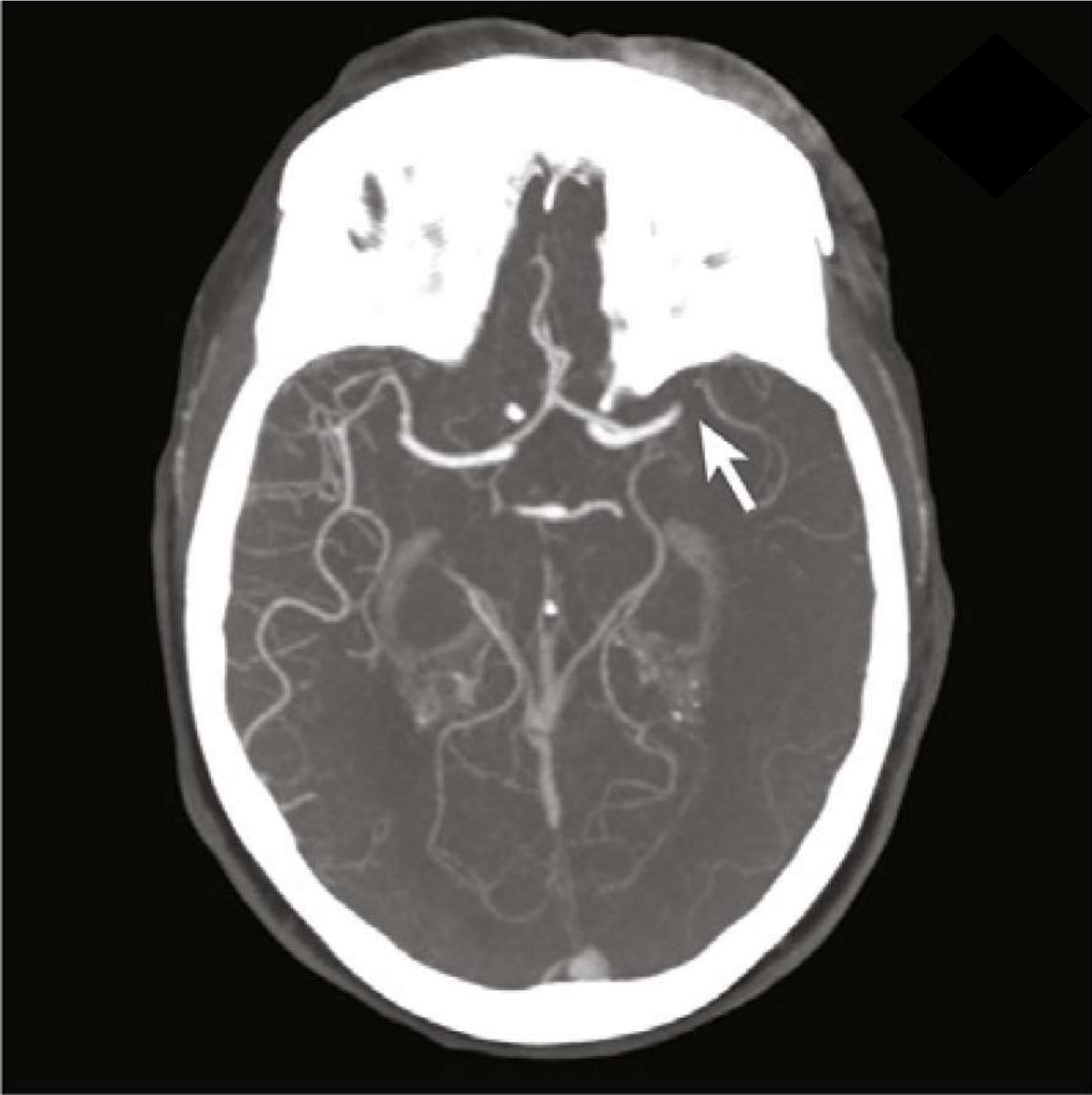
- Fibrinolisi con rTPA

## Vasi Grandi

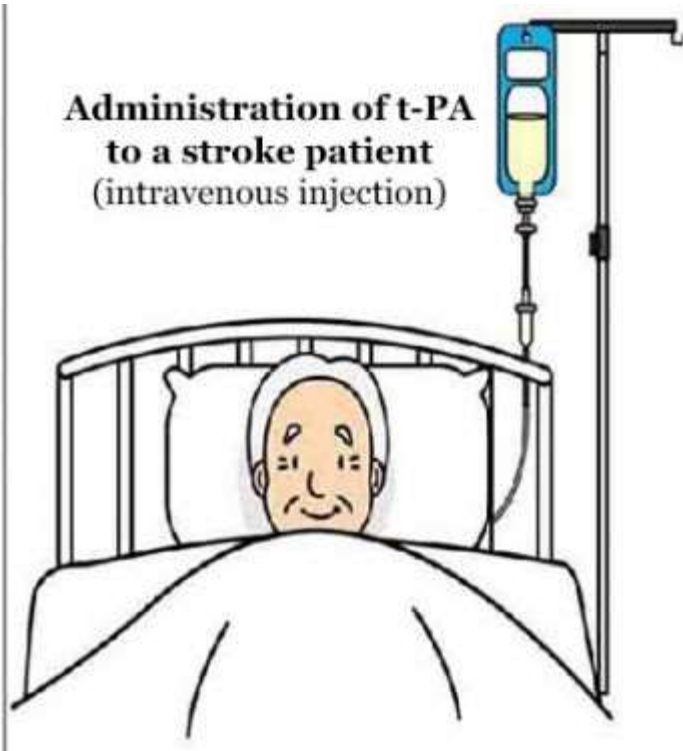
Fibrinolisi con rTPA +  
Trombectomia I.A.



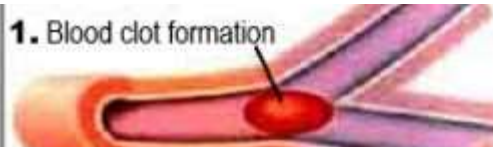




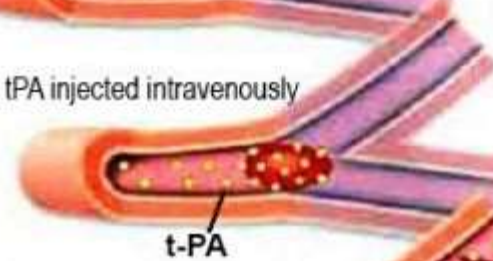
**Administration of t-PA  
to a stroke patient  
(intravenous injection)**



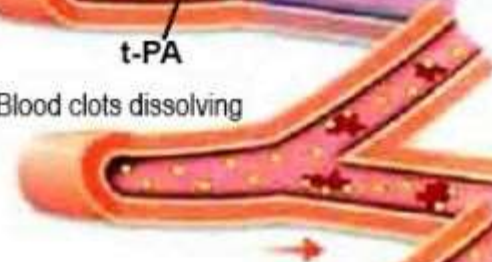**1. Blood clot formation**



**2. tPA injected intravenously**



**3. Blood clots dissolving**



**4. Restored blood flow**

